

Images in clinical medicine



One case of condyloma acuminata

 Lin-na Lv,  Zhuang-li Tang

Corresponding author: Zhuang-li Tang, The Second Affiliated Hospital of Zhejiang University School of Medicine, Hangzhou, China. lln199010@163.com

Received: 13 Feb 2024 - **Accepted:** 22 Mar 2024 - **Published:** 09 Apr 2024

Keywords: Condyloma acuminata

Copyright: Lin-na Lv et al. Pan African Medical Journal (ISSN: 1937-8688). This is an Open Access article distributed under the terms of the Creative Commons Attribution International 4.0 License (<https://creativecommons.org/licenses/by/4.0/>), which permits unrestricted use, distribution, and reproduction in any medium, provided the original work is properly cited.

Cite this article: Lin-na Lv et al. One case of condyloma acuminata. Pan African Medical Journal. 2024;47(177). 10.11604/pamj.2024.47.177.42971

Available online at: <https://www.panafrican-med-journal.com//content/article/47/177/full>

One case of condyloma acuminata

Lin-na Lv¹, Zhuang-li Tang^{1,&}

¹Linping Campus, The Second Affiliated Hospital of Zhejiang University School of Medicine, Hangzhou, China

&Corresponding author

Zhuang-li Tang, The Second Affiliated Hospital of Zhejiang University School of Medicine, Hangzhou, China

Image in medicine

A 16-year-old man presented to the dermatological department with a chronic history of cauliflower-like mass on the penis. He recalled that he first found several mung bean-sized papules on the glans without ulcers or bleeding but adopted no treatments. Thereafter the papules were gradually spread to the prepuce and the sizes of the initial lesions were enlarged dramatically. He complained of occasional itch and tingling on the glans but denied urethral discharge. On physical examination, the vital signs were within the normal ranges. The expanding and reddish papules and plaque were loosely attached to the glans and prepuce but the shaft of the penis was spared. Weighting pros and cons and after

fully informed consent, we started with fractional surgery to remove the majority and the pathological examination confirmed the diagnosis. Fulguration was utilized on the remaining mass

and thereafter 10 sessions of hyperthermia treatment were proposed. Punctually, the lesion completely diminished. No recurrence was detected within 6 months of follow-ups.

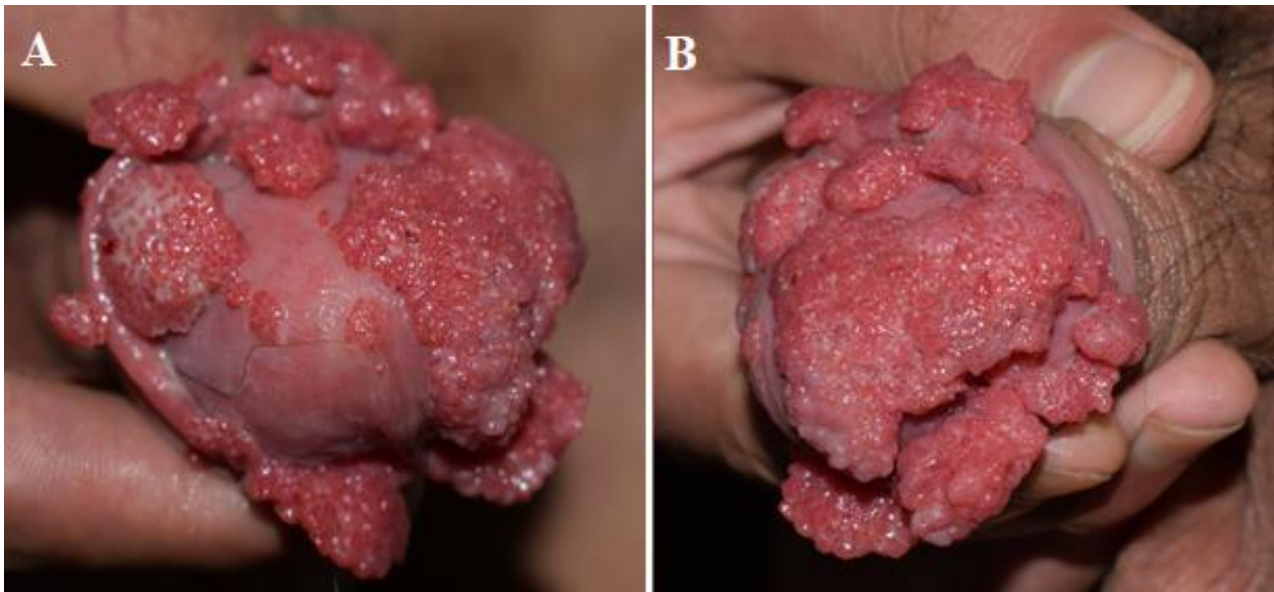


Figure 1: A,B) condyloma acuminata in a young Chinese man