


Images in clinical medicine

Post-COVID-19 related bleeding at unusual sites: add paravertebral hematomas to the list

 Nikolaos Sabanis, Achilleas Betsikos

Corresponding author: Nikolaos Sabanis, Department of Nephrology, General Hospital of Trikala, Trikala, Greece. nikospsampanis@yahoo.gr

Received: 02 Jul 2023 - **Accepted:** 09 Jul 2023 - **Published:** 13 Jul 2023

Keywords: Paravertebral hematomas, post-COVID-19 bleedings, soft tissue hematoma

Copyright: Nikolaos Sabanis et al. Pan African Medical Journal (ISSN: 1937-8688). This is an Open Access article distributed under the terms of the Creative Commons Attribution International 4.0 License (<https://creativecommons.org/licenses/by/4.0/>), which permits unrestricted use, distribution, and reproduction in any medium, provided the original work is properly cited.

Cite this article: Nikolaos Sabanis et al. Post-COVID-19 related bleeding at unusual sites: add paravertebral hematomas to the list. Pan African Medical Journal. 2023;45(122). 10.11604/pamj.2023.45.122.40947

Available online at: <https://www.panafrican-med-journal.com//content/article/45/122/full>

Post-COVID-19 related bleeding at unusual sites: add paravertebral hematomas to the list

Nikolaos Sabanis^{1,&}, Achilleas Betsikos²

¹Department of Nephrology, General Hospital of Trikala, Trikala, Greece, ²Department of Internal Medicine, General Hospital of Trikala, Trikala, Greece

&Corresponding author

Nikolaos Sabanis, Department of Nephrology, General Hospital of Trikala, Trikala, Greece

Image in medicine

A 76-year-old man with a history of end-stage renal disease on hemodialysis and heparin-induced thrombocytopenia was affected by moderate COVID-19 pneumonia. He was supported with low-flow nasal cannula oxygen and received therapy with dexamethasone, ceftriaxone, remdesivir, clopidogrel and fondaparinux at prophylactic dose. During hospitalization, he experienced a new-onset of atrial fibrillation and the initial prophylactic dose of fondaparinux switched to therapeutic one. Thereafter, he remained uneventful and discharged home. After 14 days, the patient

complained of progressively worsening back pain accompanied by clinical signs of hemorrhagic shock and an extended ecchymosis on the right paravertebral region. Laboratory tests revealed severe anemia with no evidence of thrombocytopenia, hypofibrinogenemia, disseminated intravascular coagulopathy or prolonged anti-Xa activity. Chest and abdominopelvic computed tomography showed multiple bilateral hematomas located in the erector spinae muscles, with no evidence of active bleeding. Conservative treatment was efficient

and gradual absorption of hematomas was observed. Non-traumatic soft tissue hematomas at unusual sites have been described in limited cases of COVID-19 affected patients with multiple underlying comorbidities, early in the course of the disease and predominantly in association with critical illness and systemic anticoagulation use. Therefore, this is a unique case of delayed onset of multiple paravertebral hematomas in association with treatment with fondaparinux, in a post-COVID-19 hemodialysis patient.

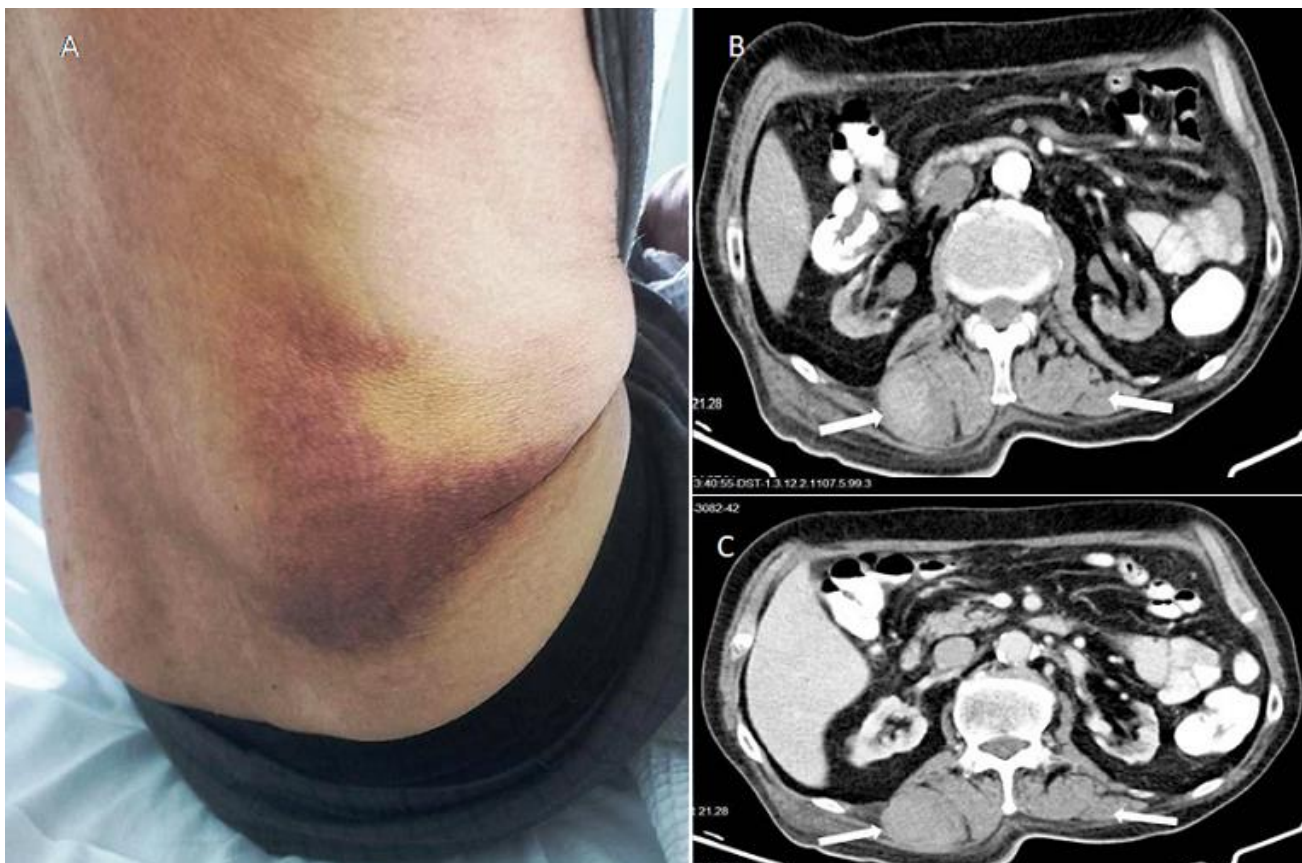


Figure 1: A) extended ecchymosis on the right flank region; B, C) multiple bilateral hematomas in the erector spinae muscles